



**PATIENT**

Zuzu Karas

**SPECIES**

Canine

**BREED**

Shih Tzu Mix

**SEX**

Male Neutered

**AGE**

10 years

**WEIGHT**

11.25lbs

**INTERPRETED BY**

Maggie Machen  
Lamy, DVM  
DACVIM (Cardiology)

**IMAGING**

**PERFORMED BY**

Pamela Harrigan,  
RDCS

**HOSPITAL NAME**

Mass Veterinary  
Services

**REFERRING VET**

Dr. Masloski

**INVOICE**

25785

**DATE**

8/16/22

**PRESENTING CLINICAL SIGNS**

History: Recheck echo. History chronic valvular disease - Stage B2. Current presentation: Zuzu is currently doing well. Good appetite. He does have some exercise intolerance in the heat and humidity. On exam: NSR, grade IV/VI murmur with PMI left apical area radiating to right, PSS, lung fields clear. BP: 120-130mmHg. current medications: 1) Pimobendan/vetmedin 1.25mg 1 tab twice a day 2) Cosequin daily \*No sedation for study.

-Pertinent previous echo findings (2/15/22 Maggie Machen Lamy, DVM, DACVIM-Cardiology): LA 2.1 cm; LA:Ao 1.8; LV 3.1 cm; moderate LAE; mild LVE; moderate MR; mild TR (2.7 m/s).

**ECHOCARDIOGRAM FINDINGS**

2D, m-mode, color flow and Doppler imaging is available.

**Left ventricle:** The LV diameter is mildly increased with hyperdynamic function. LV wall thicknesses are normal.

**Left atrium:** The left atrium is moderately dilated.

**Mitral valve:** The mitral valve is diffusely thickened with mild prolapse into the left atrial lumen. Moderate eccentric mitral regurgitation with a normal velocity.

**Aortic valve/Aorta:** The aortic valve is normal in morphology and mobility. Normal aortic outflow velocity; laminar flow. No aortic insufficiency.

**Right ventricle:** Normal right ventricular diameter and morphology indicating no overt evidence of pulmonary arterial hypertension.

**Right atrium:** Normal RA dimension.

**Tricuspid valve:** The tricuspid valve appears mildly thickened with mild tricuspid regurgitation. Normal velocity.

**Pulmonic valve/Pulmonary artery:** The pulmonic valve is normal in morphology and mobility. No pulmonic insufficiency. Normal RVOT velocity; laminar flow.

**Pericardium/other:** No pericardial or pleural effusion noted. No obvious cardiac masses.

**Heart rhythm:** ECG reveals a sinus rhythm with an average HR of 180bpm.

**2-Dimensional Measurements**

Ao diam (cm)	1.3
LA diam (cm)	2.3
LA:Ao (Swe)	1.8
IVS thickness (cm)	0.61
LVID diastole (cm)	2.8
PW thickness (cm)	0.70
LVID systole (cm)	1.4
FS (%)	50

**Doppler Measurements**

PV Vmax (m/s)	0.8
AoV Vmax (m/s)	1.4
MR Vmax (m/s)	5.1
TR Vmax (m/s)	2.7
TR PG (mmHg)	29

**INTERPRETATION OF THE FINDINGS**

Chronic degenerative valve disease persists with continued stability. The left heart dimensions are stable without obvious progressive dilation. Mild TR is unchanged with normal pulmonary pressures. No additional issues are identified.

Given these findings, continue Pimobendan is recommended as prescribed. No additional medications are clearly warranted.

Given stable LA disease, this is unlikely to be related to exercise intolerance and other possible causes should be considered.



**PATIENT**

Zuzu Karas

**SPECIES**

Canine

**BREED**

Shih Tzu Mix

**SEX**

Male Neutered

**AGE**

10 years

**WEIGHT**

11.25lbs

**INTERPRETED BY**

Maggie Machen Lamy, DVM DACVIM (Cardiology)

**IMAGING PERFORMED BY**

Pamela Harrigan, RDCS

**HOSPITAL NAME**

Mass Veterinary Services

**REFERRING VET**

Dr. Masloski

**INVOICE**

25785

**DATE**

8/16/22

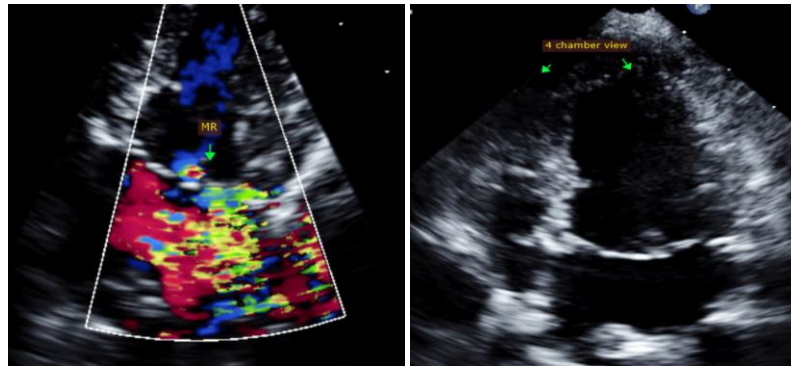
**RECOMMENDATIONS**

- Continue Pimobendan as prescribed.
- Omega fatty acid supplementation and mild salt restriction may be of some long-term benefit.
- Anesthetic risk is considered mild if needed. Cardiac protective drug choices (opioid/benzodiazepine premedication, propofol or alfaxalone induction, isoflurane gas) are recommended. Pre-oxygenate for 5-10 minutes prior to induction. Monitor for arrhythmias, hypotension, and hypoxia both intra and post-operatively and intervene as necessary. Mild IV fluid restriction is recommended to avoid fluid overload. Avoid heart rate stimulating drugs such as atropine unless clinically indicated.
- Monitor for development of a cough, labored breathing, exercise intolerance or collapse episodes.

**PLAN**

- Recommend conservative monitoring with a recheck echocardiogram in 6-8 months, sooner if any development of clinical signs.

**IMAGES**



The information and recommendations provided are based on the images presented by the referring veterinarian. No evaluation can be communicated regarding pathology that was not visible in the image/video clips provided.

Thank you for this referral. This report was generated using transcription software, and minor dictation errors may be present. If the clinical or image interpretation does not parallel your findings or if I can be of any further assistance, please contact me.

Maggie Machen Lamy, DVM  
Diplomate of the American College of Veterinary Internal Medicine (Cardiology)  
info@sonopath.com

Echocardiogram performed by: Pamela Harrigan, RDCS  
Pet Animal Ultrasound Service (4paus.com)